



Case report

A case of vascular leiomyosarcoma diminished with intravenous leiomyomatosis

Özlem Nuray Sever^{a,*}, Mehmet Sökücü^b^a Gaziantep University Faculty of Medicine, Department of Medical Oncology, Turkey^b Sanko University Faculty of Medicine, Department of Pathology, Turkey

ARTICLE INFO

Article history:

Received 21 November 2018

Received in revised form

19 February 2019

Accepted 4 March 2019

Available online 14 March 2019

Keywords:

Vascular leiomyosarcoma

Intravenous leiomyomatosis

Differential diagnosis

ABSTRACT

Leiomyosarcoma is a rare mesenchymal tumor of smooth muscle origin and up to 5% is caused by vascular smooth muscle. Vascular leiomyosarcoma is more common in women. The disease is often caused by large veins. Depending on the localization of the vein, different clinical pictures may be seen. As it is a rare tumor, there are difficulties in the clinical and pathological diagnosis of the disease. Standard recommendations on treatment are also not available.

A 36-year-old female patient was admitted to our hospital with swelling in her left lower extremity. Physical examination of the patient was consistent with venous insufficiency findings. In the lower extremity venous doppler ultrasonography, there was grade 1 reflux in the left femoral vein. Medical treatment was performed. The patient was called for control after 1 month. The patient was re-admitted with deep vein thrombus. A repeat radiological examination revealed a mass in the left iliac vein. The patient was operated. The pathological diagnosis of the patient was evaluated in two centers. Finally, it was decided that the diagnosis was compatible with vascular leiomyosarcoma.

Intravascular leiomyosarcoma can be overlooked in both clinical practice, radiological evaluation and histopathological examination because of its very rare occurrence.

© 2019 Turkish Society of Medical Oncology. Production and hosting by Elsevier B.V. This is an open access article under the CC BY-NC-ND license (<http://creativecommons.org/licenses/by-nc-nd/4.0/>).

1. Introduction

Leiomyosarcoma is a small proportion of malignant soft tissue tumours seen in adults. In the literature, the incidence varies between 5 and 10%.^{1,2} Tumor origin is observed in 4 main locations: intraabdominal/retroperitoneal, cutaneous, subcutaneous and vascular.² The leiomyosarcoma of vascular origin was first described by Perl in 1871 in a case originating from the inferior vena cava wall.³ Vascular leiomyosarcomas often affect the veins and vena cava inferior is the most frequently affected vein.⁴ Due to its rarity, information about treatment and prognosis is limited. We report a 36-year-old female patient who was diagnosed with vascular leiomyosarcoma while being followed up for venous insufficiency.

1.1. Case report

A 36-year-old female patient was admitted to the hospital on

February 2018 because she noticed swelling in her left leg. Her physical examination revealed edema, which was more prominent in the left lower extremity, but was not accompanied by pain and redness. Apart from this, there was no pathological finding in physical examination and anamnesis. We requested lower extremity venous doppler ultrasonography with preliminary diagnosis of venous insufficiency for initial radiological evaluation. Valsalva maneuver in the doppler usg showed grade 1 reflux in the left popliteal vein and left superficial femoral vein. The medical treatment of the patient was carried out and she was called for control after 1 month. During the follow-up examination, the left lower extremity edema was partially regressed and the patient was called for a follow-up period of 6 months. Approximately 5 months later, the patient presented again due to swelling and redness in the left lower extremity. Physical examination revealed edema, redness and temperature increase in the left limb as well as a palpable mass in the left groin. The left lower extremity venous doppler usg examination was requested again. A 35 * 25 mm lobulated confined heterogeneous hypoechoic area was observed in the left external iliac vein-main femoral vein junction. Left main femoral vein could not be visualized at this location, CT angiography was recommended for possible thrombus and external compression. CT angiography showed a mass lesion with a lobulated contour of

* Corresponding author. Gaziantep University, School of Medicine, Department of Medical Oncology, Şahinbey, Gaziantep, Turkey.

E-mail address: ozlem.sever@hotmail.com (Ö.N. Sever).

Peer review under responsibility of Turkish Society of Medical Oncology.

heterogeneous opacification of the left external inguinal vein at the left inguinal region, approximately 32 * 24 mm in size, and a malignant thrombus within the adjacent left main femoral vein. The patient was operated. A mass originated from the left iliac vein was seen in the operation, resected from the proximal and distal, and repaired with the right saphenous vein graft. Pathological examination of the specimen revealed ischemic necrotic changes and cross-sectional bundles with hyaline degeneration and tumoral lesion in the form of vascular structures. A portion of the tumor that was separated from the peripheral vascular structure was composed of mesenchymal cells with blunt-tip spindle nuclei in the spherical cell feature. The mitotic activity index was counted as an average of 4 in 10 large magnification fields. Immunohistochemical examination revealed a positive reaction with desmin and smooth muscle actin in tumor cells. Vascular wall staining was detected with CD-31. Ki-67 proliferation index was evaluated as 20%, and findings were evaluated as compatible with intravenous leiomyomatosis. The patient was asked for a second pathology opinion because of the rare occurrence. In the second pathology, there were 5 mitosis in 10 large magnification fields and necrosis were observed. As a result of immunohistochemical examinations, smooth muscle actin and desmin were positive, Ki-67 proliferation index was found to be higher, and p53 and PHH3 were applied, and the diagnosis was consistent with leiomyosarcoma (Figs. 1–4). The patient was referred to medical oncology and radiation oncology outpatient clinics. Postoperative adjuvant radiotherapy administered to the patient. The patient did not have any abnormalities in the PET-CT and was recommended to come to the control every 3 months.

2. Discussion

Leiomyosarcoma is a rare mesenchymal tumor of smooth muscle origin. It is usually seen in the retroperitoneal area in the abdominal cavity or uterus.⁴ However, up to 5% is caused by vascular smooth muscle, while the majority of vascular leiomyosarcomas are venous.⁵ As it is a rare tumor, studies on vascular leiomyosarcomas in the literature are reported as case reports or case series. In these studies, it has been reported that vascular leiomyosarcoma usually originates from the inferior vena cava or from the retroperitoneal veins (iliac, renal, spermatic and ovarian veins). Fujita et al. reported a case of leiomyosarcoma of the vena cava inferior origin extending to the right atrium and reported that the disease was 2.5 times more common in women as a result of a literature review. The disease is frequently seen in the 5th and 6th decades.⁶

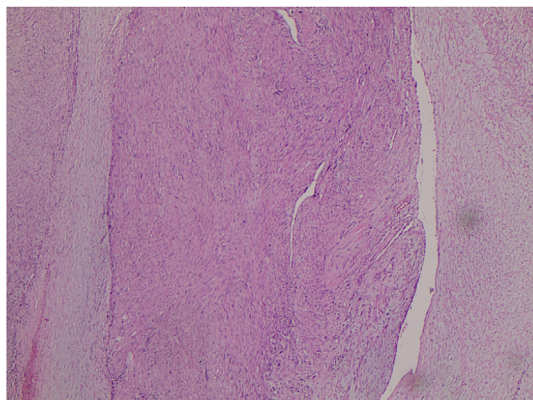


Fig. 1. Spindle cell proliferation is almost completely obliterated to the vessel lumen.

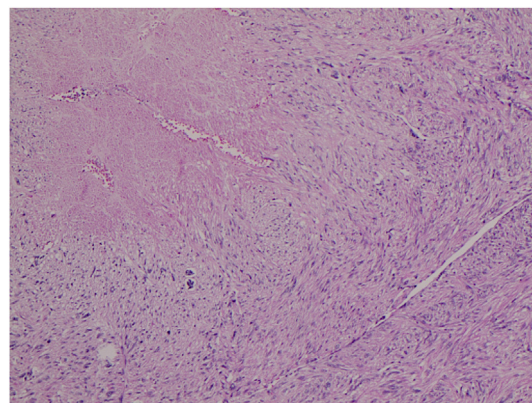


Fig. 2. Neoplastic tissue with necrotic, blunt-ended nuclei and short bundles.

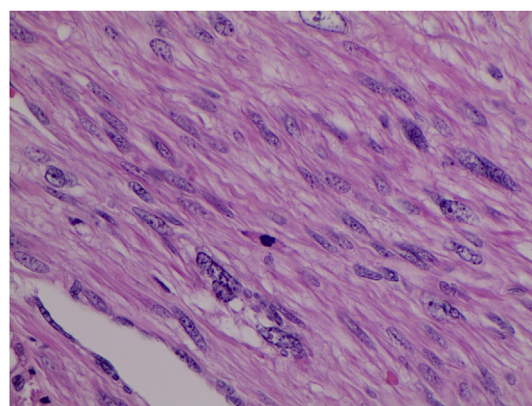


Fig. 3. Atypical mitosis is seen in the middle.

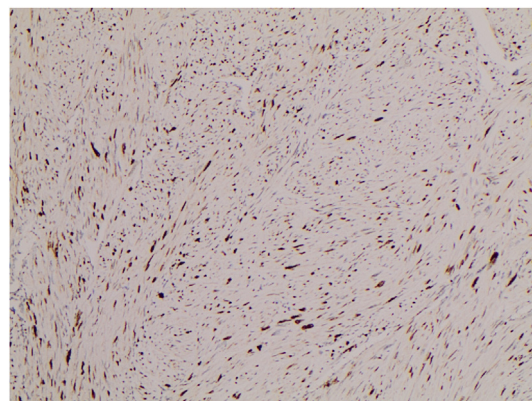


Fig. 4. Immunohistochemically Ki-67 proliferation index varies in different areas.

The symptoms and signs related to the disease depends on site (localization of the vascular structure), size and growth pattern (extraluminal or intraluminal or mixed) of the tumor. Intraluminal tumours present with features of venous obstruction But most of the tumours have extraluminal growth pattern. Pain and discomfort are the most frequent symptoms and 5,8% of patients did not have any symptoms. Luminal sarcomas are often arterial, whereas mural sarcomas tend to be located venously, and have a better prognosis.^{7,8}

Computed Tomography and Magnetic Resonance Imaging have high diagnostic sensitivity (78% and 95%) and specificity (96% and

100%) respectively, for intravascular thrombosis. MR venogram or CT angiography are considered in preoperative work up as determining the origin of tumor.⁹ There is not enough data in the literature about the differentiation of intravenous leiomyomatosis and vascular leiomyosarcoma from each other with imaging technics.

Optimal treatment is yet to be established due to low incidence. Complete surgical resection is the primary treatment of the disease. Role of postoperative radiotherapy and chemotherapy for venous leiomyosarcoma is not clear. Postoperative radiotherapy may help in local control in case of incomplete tumor resection. Adjuvant radiotherapy is recommended in selected cases (when the surgical margin is close or positive, high grade and extremity localization, etc.). Adjuvant chemotherapy is not recommended. However, these treatment recommendations are controversial because they are a rare malignancy.¹⁰

The duration of survival depends on the size, localization of the tumor, the presence of complete surgical resection, age of the patient, histological grade, mitotic activity and stage of the tumor. The effectiveness of chemotherapy and radiotherapy is limited. The mean survival time was 6.7 years and the 5-year survival rate was 50% after complete resection.^{11,12} In the course of intravascular leiomyosarcoma, lung and liver metastases are most common. The prognosis of intravascular leiomyosarcomas is worse than other leiomyosarcomas and may be due to their potential for early hematogenous metastasis because of their vascular origin.^{11,12}

The definitive diagnosis of intravascular leiomyosarcoma can be made by histological examination and immunohistochemical evaluation. In histological examination, the appearance of the typical leiomyosarcoma is similar in different localizations, but in the spindle cells, the fascicular growth pattern and the tumor cells and the vascular wall are intertwined. Unlike other leiomyosarcomas, necrosis and hemorrhage are uncommon in intravascular leiomyosarcomas.¹³ Immunohistochemical techniques are valuable in the diagnosis and differential diagnosis. It shows positive immunoreactivity with vimentin, desmin, calponin and smooth muscle myosin heavy chain while shows negative immunoreactivity with S-100, alpha-inhibin and CD117.¹⁴ Especially in women, intravascular leiomyosarcoma should be differentiated from intravenous leiomyomatosis.

Differential diagnosis of vascular leiomyosarcoma includes other sarcomas such as fibrosarcoma, synovial sarcoma, neurofibroma and hemangioperistoma. Leiomyomatosis is a benign

neoplasm and is often caused by uterine or extrauterine venous system. Leiomyosarcoma is a rare malignant neoplasm and is prone to originate from larger veins.

We report a case of intravascular leiomyosarcoma with iliac vein origin. Intravascular leiomyosarcoma can be overlooked in both clinical practice, radiological evaluation and histopathological examination because of its very rare occurrence.

Conflict of interest

There is no conflict of interest between the authors.

References

1. Shimoda H, Oka K, Otani S, et al. Vascular leiomyosarcoma arising from the inferior vena cava diagnosed by intraluminal biopsy. *Virchows Arch.* 1998;433(1):97–100.
2. Tilkorn DJ, Lehnhardt M, Hauser J, et al. Intravascular leiomyosarcoma of the brachiocephalic region – report of an unusual tumour localisation: case report and review of the literature. *World J Surg Oncol.* 2008;6:113.
3. Perl L. Ein Fall von Sarkom der Vena cava inferior. *Virchows Arch.* 1871;53:378–383.
4. Weiss SW, Goldblum JR. *Enzinger and Weiss's Soft Tissue Tumors.* 4th. St. Louis, MO: Mosby; 2001 (Leiomyosarcoma).
5. Tilkorn DJ, Hauser J, Ring A, et al. Leiomyosarcoma of intravascular origin—a rare tumor entity: clinical pathological study of twelve cases. *World J Surg Oncol.* 2010;8:103. <https://doi.org/10.1186/1477-7819-8-103>.
6. Fujita S, Takahashi H, Kanzaki Y, et al. Primary leiomyosarcoma in the inferior vena cava extended to the right atrium: a case report and review of the literature. *Case Rep Oncol.* 2016;9(3):599–609.
7. Burke AP, Virmani R. Sarcomas of the great vessels. *Clinicopathologic stud Cancer.* 1993;71:1761–1773.
8. Székely E, Kulka J, Miklós I, Kaliszky P. Leiomyosarcomas of great vessels. *Pathol Oncol Res.* 2000;6:233–236. <https://doi.org/10.1007/BF03032379>.
9. Oliveira N, Dias E, Lima R, et al. Primary iliac venous leiomyosarcoma: a rare cause of deep vein thrombosis in a young patient. *Case Rep Med.* <https://doi.org/10.1155/2011/123041>.
10. Wu W, Zhao X, Wang Y, et al. Leiomyosarcoma of the splenic vein: a case report. *Oncol Lett.* 2017;14(1):977–980.
11. Mingoli A, Cavallaro A, Sapienza P, et al. International registry of inferior vena cava leiomyosarcoma: analysis of a world series on 218 patients. *Anticancer Res.* 1996;16:3201–3205.
12. Hines OJ, Nelson S, Quinones-Baldrich WJ, Eilber FR. Leiomyosarcoma of the inferior vena cava: prognosis and comparison with leiomyosarcoma of other anatomic sites. *Cancer.* 1999;85:1077–1083.
13. Hilliard NJ, Heslin MJ, Castro CY. Leiomyosarcoma of the inferior vena cava: three case reports and review of the literature. *Ann Diagn Pathol.* 2005;9(5):259–266.
14. González-Cantú YM, Tena-Suck ML, Serna-Reyna S, et al. Leiomyosarcoma of vascular origin: case report. *Case Rep Clin Pathol.* 2015;2(4):60–64.