

## CASE REPORT

DOI: 10.37047/jos.2020-75309

# Pituitary Gland Metastasis of Breast Cancer: A Rare Case Report and Review of the Literature

 Melih ŞİMŞEK<sup>a</sup><sup>a</sup>Yozgat City Hospital, Yozgat, TURKEY

**ABSTRACT** Pituitary gland metastasis is an uncommon situation seen in advanced stages of malignancies. The diagnosis of advanced cancer with pituitary metastasis is a rarer presentation. Lung and breast cancers are the most common form of primary malignancies that metastasize to the pituitary gland. Mucinous adenocarcinoma is a rare histological subtype of breast cancer. Here, we report a case of a patient diagnosed with pituitary gland metastasis who had a long survival achieved by a multimodality treatment approach. The patient was diagnosed with the excisional biopsy of a pituitary gland lesion. After a partial response to chemotherapy, letrozole treatment was initiated. After eight years, a recurrent lesion was determined in her right breast. She underwent a right modified radical mastectomy and axillary dissection and letrozole treatment was continued. Follow-up and treatment are still ongoing. In this case, multimodal treatment was effective in achieving long-term survival. Thus, metastasis should be considered in the differential diagnosis of pituitary lesions.

**Keywords:** Breast cancer; mucinous carcinoma; pituitary metastasis

Metastasis to the pituitary gland is a very rare complication of systemic malignancies and accounts for around 1% of all pituitary tumor resections.<sup>1,2</sup> It is typically recorded in the geriatric patients with an incidence rate of 1% to 4% of all cancers.<sup>3</sup> Occasionally, advanced cancer is diagnosed with symptomatic pituitary metastasis.<sup>4</sup> The most common primary malignancies are breast cancer in women and lung cancer in men, and these tumors constitute two-third of all cases.<sup>1,5</sup> Moreover, various malignancies, including prostate cancer, thyroid cancer, kidney cancer, and gastrointestinal system cancers can metastasize to pituitary gland.<sup>6,7</sup> The extent of primary cancer contributes to the choice of treatment modality, including surgical excision, radiotherapy, and chemotherapy.<sup>6</sup>

The most common type of cancer in women is breast cancer, and the vast majority is invasive ductal carcinoma (IDC).<sup>8</sup> A very rare histological sub-

type of IDC is mucinous adenocarcinoma, also known as colloidal breast cancer. It has a large amount of extracellular mucin. Mucinous breast cancer (MBC) can be classified into two types as pure and mixed.<sup>9,10</sup> Only 1% of MBC cases are prevalent in women younger than 35 years.<sup>11</sup> It is generally characterized as hormone receptor-positive and HER2 negative and has low grade.<sup>12,13</sup> Tumor size is usually smaller in comparison to other subtypes of breast cancer.<sup>11</sup> It has been reported that enhanced mucin production creates a barrier limiting the tumor size and also reduces the invasive capacity of the tumor.<sup>14</sup> This has been correlated with a better prognosis of this type of cancer.<sup>15,16</sup> It has a better clinical outcome than other subtypes with rare axillary lymph node metastasis, and less than 15% of the cases have metastatic disease.<sup>10,17</sup> Nodal involvement is considered to be the most important prognostic factor and has been reported in 2-14% of pure MBC and 46-

**Correspondence:** Melih ŞİMŞEK  
Yozgat City Hospital, Yozgat, TURKEY  
**E-mail:** mdmelih@gmail.com



Peer review under responsibility of Journal of Oncological Sciences.

**Received:** 06 Apr 2020

**Received in revised form:** 25 Jun 2020

**Accepted:** 09 Jul 2020

**Available online:** 16 Jul 2020

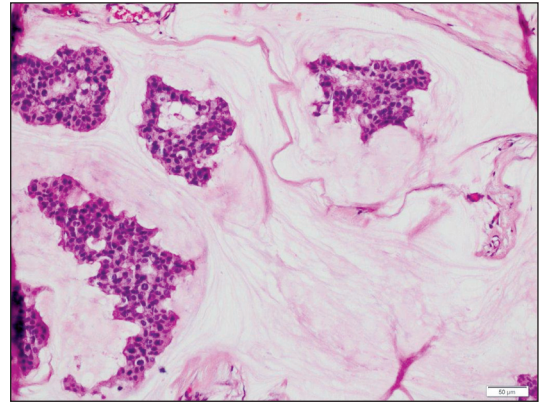
2452-3364 / Copyright © 2020 by Turkish Society of Medical Oncology. This is an open access article under the CC BY-NC-ND license (<http://creativecommons.org/licenses/by-nc-nd/4.0/>).

64% of mixed MBC.<sup>11</sup> Most of the cases are diagnosed at clinical stage 2 of the disease.<sup>9</sup> 5-year cancer-specific survival has been found to be 94%, and this rate reaches 81% at twenty years of follow-up.<sup>9,11,18</sup>

Here we aimed to report a case of a 61-year-old woman diagnosed with pituitary gland metastasis of MBC as the first manifestation of underlying cancer and who had a long survival attributed to multimodality treatment approach.

## CASE REPORT

In July 2009, a 61-year-old woman with no significant medical history was presented with sudden onset of severe headache. Emergent examination elucidated a pituitary mass lesion, whereby, she underwent total excision of the tumor via trans-nasal transsphenoidal surgery. Pathology of the specimen characterized the tumor as grade 1, estrogen receptor (ER) and progesterone receptor (PR) positive, and HER2 negative pure mucinous carcinoma. The primary lesion in the right breast, bilateral pulmonary metastatic nodules, and right surrenal gland metastasis were revealed by an in-depth diagnosis for systemic staging with PET-CT. Completion of palliative radiotherapy to the pituitary cavity where the mass lesion was excised, was followed by the administration of six cycles of CAF chemotherapy. After a partial response with chemotherapy, letrozole treatment was initiated. No sign of tumor was determined in systemic evaluation after six months of endocrine therapy. After approximately eight years of progression-free survival, in May 2018, a recurrent lesion was identified in her right breast. Because no distant metastasis was obtained in systemic evaluation, surgery was planned for the treatment of the patient. Because of social problems, she failed to refer for surgery till June 2019. After confirmation of the absence of distant metastatic disease, a right modified radical mastectomy and axillary dissection was performed. Postoperative pathology was reported as ER positive (80%), PR positive (80%), HER2 negative, grade 2, node negative (all of the 16 lymph nodes that dissected were reactive), and a maximum diameter of the tumor was 2 cm (Figure 1). After confirming the final pathology report as pT2pN0pMx, letrozole treatment



**FIGURE 1:** Light microscopic image of recurrent mucinous carcinoma in breast tissue (HE, x200).

was continued. Final systemic evaluation in October 2019 documented no recurrent or metastatic uptake in PET-CT scan. An overall survival (OS) of 11 years achieved for the patient diagnosed with pituitary gland metastasis. The follow-up and treatment of the patient are still ongoing. Informed consent was obtained from the patient.

## DISCUSSION

Pituitary gland metastasis is a rare clinical manifestation of systemic malignancies and accounts for approximately 1% of all pituitary tumor resections.<sup>1,2</sup> Pituitary metastasis at diagnosis is a much rarer event.<sup>4</sup> Any type of cancer can metastasize to the pituitary gland.<sup>6,7</sup> However, breast and lung cancers are the most prevalent form of primary cancers that metastasize to pituitary gland.<sup>1,5,7</sup> In this present case, the primary tumor originated from the breast, as reported in the literature. But the interesting point in our case was metastatic MBC at diagnosis, which is not a frequently seen clinical situation. Lymph node metastasis and distant metastasis are less common than other subtypes in the clinical course of MBC patients who generally exhibit a very favorable prognosis.<sup>19</sup>

The mean OS has been reported about six months after the occurrence of pituitary gland metastasis and a 1-year mortality rate of the cases is 90%.<sup>1</sup> However, this OS analysis mostly includes aggressive cancer types. In the case of MBC, the metastatic disease rate was found to be between 12% and 14% with a better prognosis than other breast cancer sub-

types.<sup>11,20,21</sup> Clinical data substantiated a 10-year survival rate of 90.4%.<sup>22</sup> Although our case diagnosed metastatic disease, she is still alive and reached an eleven-year OS without any clues of disease recurrence. This outcome is in agreement with the literature findings emphasizing the slow clinical progress of MBC.

MBC is more predominant among elderly women. In the largest case series of 11.400 pure MBC cases, the median age at diagnosis was reported to be 71 years as compared to 61 years in IDC patients.<sup>11</sup> Our patient was a postmenopausal female in accordance with the data in the literature but younger with 61 years of age at diagnosis. A large amount of extracellular mucin is the characteristic feature of MBC.<sup>23</sup> These tumors generally are both ER and PR positive. In this present case also, extensive extracellular mucin was present, and the tumor was ER and PR positive. It has been reported that the increased mucin production limits the tumor by forming a barrier and also decreases the invasive capacity of the tumor.<sup>14</sup> Moreover, this has been associated with a better prognosis.<sup>15,16</sup> A better clinical course than other subtypes has been illustrated with rare axillary lymph node metastasis, and less than 15% of the cases have metastatic disease.<sup>10,17</sup> But in this present case, the patient was detected with the pituitary gland, the surrenal gland, and bilateral lung metastasis of MBC.

The traditional treatment options for pituitary metastasis, including surgical excision, radiotherapy, and chemotherapy, depend on the extent of primary cancer, and the aim of these therapies is mostly palliative relief.<sup>6,24</sup> The rarity of MBC makes it difficult to determine the treatment strategies. The most important source of the data on outcome and treatments are derived from small case series and case reports. For this reason, assessment and planning of the most appropriate treatment approach become inevitable. In our case, following the total excision of pituitary tumor, radiotherapy has been administered to the tumor cavity in the pituitary gland and thereafter, systemic chemotherapy with CAF regimen has initiated. Letrozole was the choice of drug as the endocrine treatment following partial response with systemic chemotherapy. Surgery was considered as the funda-

mental treatment strategy followed by adjuvant chemotherapy and radiotherapy when indicated except for HER-2 overexpressing MBC.<sup>25</sup> In this present case, when recurrence ensued after eight years and no metastatic disease was identified, modified radical mastectomy and axillary dissection were opted as surgical treatment of the patient. With the known effectiveness of endocrine therapy in hormone receptor positive tumors, adjuvant letrozole treatment was continued in our patient.<sup>21</sup>

## CONCLUSION

Because of its rarity, tailored treatment options are absent for pituitary gland metastasis of any primary cancer. Similar treatment modalities such as surgery and radiotherapy are used regardless of underlying cancer. In this present case, the patient who had case who had metastatic disease at diagnosis, may be because of mucinous carcinoma histology, long-term survival has been achieved with multimodal treatment including metastasectomy, radiotherapy, chemotherapy, surgery intended for primary lesion, and endocrine therapy that have been administered at different time points. In this case, it was quite evident that long-term progression-free survival and OS could be achieved with proper treatment at the proper time in MBC, even if it was in the metastatic stage. It is necessary to emphasize that detailed and true history-taking and physical examinations are inevitable for the diagnosis of any disease.

### Source of Finance

*During this study, no financial or spiritual support was received neither from any pharmaceutical company that has a direct connection with the research subject, nor from a company that provides or produces medical instruments and materials which may negatively affect the evaluation process of this study.*

### Conflict of Interest

*No conflicts of interest between the authors and / or family members of the scientific and medical committee members or members of the potential conflicts of interest, counseling, expertise, working conditions, share holding and similar situations in any firm.*

### Authorship Contributions

*This study is entirely author's own work and no other author contribution.*

## REFERENCES

- Komninos J, Vlassopoulou V, Protopapa D, et al. Tumors metastatic to the pituitary gland: case report and literature review. *J Clin Endocrinol Metab.* 2004;89(2):574-580. [[Crossref](#)] [[PubMed](#)]
- Shayani Nasab M, Jafari M, Mosavi Bahar SH, Shayani Nasab H. Endoscopic management of unusual metastasis of renal cell carcinoma to the sinonasal area. *Acta Medica Iranica.* 2009;47(5):419-421.
- Yang L, Yu SY, Hu GY. Pituitary metastasis from a renal cell carcinoma progressed after sorafenib treatment. *Chin J Cancer.* 2013;32(6):353-356. [[Crossref](#)] [[PubMed](#)] [[PMC](#)]
- Teeares RJ, Silverman EM. Clinicopathologic review of 88 cases of carcinoma metastatic to the pituitary gland. *Cancer.* 1975;36(1):216-220. [[Crossref](#)] [[PubMed](#)]
- Fassett DR, Couldwell WT. Metastases to the pituitary gland. *Neurosurg Focus.* 2004;16(4):E8. [[Crossref](#)] [[PubMed](#)]
- Kim YH, Lee BJ, Lee KJ, Cho JH. A case of pituitary metastasis from breast cancer that presented as left visual disturbance. *J Korean Neurosurg Soc.* 2012;51(2):94-97. [[Crossref](#)] [[PubMed](#)] [[PMC](#)]
- Brown HM, McCutcheon IE, Leeds NE, Schomer DS, Luna MA, Fuller GN. Melanoma metastatic to central neurocytoma: a novel case of tumor-to-tumor metastasis. *J Neurooncol.* 2003;61(3):209-214. [[Crossref](#)] [[PubMed](#)]
- Siegel RL, Miller KD, Jemal A. Cancer statistics, 2020. *CA Cancer J Clin.* 2020;70(1):7-30. [[Crossref](#)] [[PubMed](#)]
- Zhang L, Jia N, Han L, Yang L, Xu W, Chen W. Comparative analysis of imaging and pathology features of mucinous carcinoma of the breast. *Clin Breast Cancer.* 2015;15(2):e147-e154. [[Crossref](#)] [[PubMed](#)]
- Tseng HS, Lin C, Chan SE, et al. Pure mucinous carcinoma of the breast: clinicopathologic characteristics and long-term outcome among Taiwanese women. *World J Surg Oncol.* June 2013;11:139. [[Crossref](#)] [[PubMed](#)] [[PMC](#)]
- Di Saverio S, Gutierrez J, Avisar E. A retrospective review with long term follow up of 11,400 cases of pure mucinous breast carcinoma. *Breast Cancer Res Treat.* 2008;111(3):541-547. [[Crossref](#)] [[PubMed](#)]
- Diab SG, Clark GM, Osborne CK, Libby A, Allred DC, Elledge RM. Tumor characteristics and clinical outcome of tubular and mucinous breast carcinomas. *J Clin Oncol.* 1999;17(5):1442-1448. [[Crossref](#)] [[PubMed](#)]
- Nakagawa T, Sato K, Moriwaki M, et al. Successful endocrine therapy for locally advanced mucinous carcinoma of the breast. *Breast J.* 2012;18(6):632-633. [[Crossref](#)] [[PubMed](#)]
- Barkley CR, Ligibel JA, Wong JS, Lipsitz S, Smith BL, Golshan M. Mucinous breast carcinoma: a large contemporary series. *Am J Surg.* 2008;196(4):549-551. [[Crossref](#)] [[PubMed](#)]
- Kryvenko ON, Chitale DA, Yoon J, Arias-Stella 3rd J, Meier FA, Lee MW. Precursor lesions of mucinous carcinoma of the breast: analysis of 130 cases. *Am J Surg Pathol.* 2013;37(7):1076-1084. [[Crossref](#)] [[PubMed](#)]
- Li CI. Risk of mortality by histologic type of breast cancer in the United States. *Horm Cancer.* 2010;1(3):156-165. [[Crossref](#)] [[PubMed](#)]
- Vo T, Xing Y, Meric-Bernstam F, et al. Long-term outcomes in patients with mucinous, medullary, tubular, and invasive ductal carcinomas after lumpectomy. *Am J Surg.* 2007;194(4):527-531. [[Crossref](#)] [[PubMed](#)]
- Shet T. Time to change the way we diagnose mucinous carcinomas of the breast. *Hum Pathol.* 2014;45(2):434-435. [[Crossref](#)] [[PubMed](#)]
- Skotnicki P, Sas-Korczyńska B, Strzepek L, et al. Pure and mixed mucinous carcinoma of the breast: a comparison of clinical outcomes and treatment results. *Breast J.* 2016;22(5):529-534. [[Crossref](#)] [[PubMed](#)]
- Lei L, Yu X, Chen B, Chen Z, Wang X. Clinicopathological characteristics of mucinous breast cancer: a retrospective analysis of a 10-year study. *PLoS One.* 2016;11(5):e0155132. [[Crossref](#)] [[PubMed](#)] [[PMC](#)]
- Ranade A, Batra R, Sandhu G, Chitale RA, Balderacchi J. Clinicopathological evaluation of 100 cases of mucinous carcinoma of breast with emphasis on axillary staging and special reference to a micropapillary pattern. *J Clin Pathol.* 2010;63(12):1043-1047. [[Crossref](#)] [[PubMed](#)]
- Komaki K, Sakamoto G, Sugano H, Morimoto T, Monden Y. Mucinous carcinoma of the breast in Japan. A prognostic analysis based on morphologic features. *Cancer.* 1988;61(5):989-996. [[Crossref](#)] [[PubMed](#)]
- Bae SY, Choi MY, Cho DH, Lee JE, Nam SJ, Yang JH. Mucinous carcinoma of the breast in comparison with invasive ductal carcinoma: clinicopathologic characteristics and prognosis. *J Breast Cancer.* 2011;14(4):308-313. [[Crossref](#)] [[PubMed](#)] [[PMC](#)]
- McCutcheon IE, Waguespack SG, Fuller GN, Couldwell WT. Metastatic melanoma to the pituitary gland. *Can J Neurol Sci.* 2007;34(3):322-327. [[Crossref](#)] [[PubMed](#)]
- Marrazzo E, Frusone F, Milana F, et al. Mucinous breast cancer: a narrative review of the literature and a retrospective tertiary single-centre analysis. *Breast.* February 2020;87-92. [[Crossref](#)] [[PubMed](#)] [[PMC](#)]