



## Letter to the Editor

## Metastatic anal cloacogenic cell carcinoma misdiagnosed as urothelial carcinoma with long survival

## To The Editor:

Cloacogenic cancers are very rare disease of the anal canal and account for 1–3% of the all anal canal malignities.<sup>1</sup> It originate from cloacogenic remnant of the cloacal membrane of the embryo and localize transitional or cloacogenic zone of anal canal. Most of the cases are local or loco-regional and can be treated by surgery and radiotherapy with or without chemotherapy. However, there are little data about metastatic cloacogenic cancer and its treatment. We present here a case metastatic cloacogenic anal cancer treated with cisplatin and 5 fluoruracil.

A 55-years men patient who presented with hematuria diagnosed invasive uroepithelial carcinoma of bladder in 2005. He underwent radical cystostomy and treated with 3 cycles of gemcitabin and cisplatin as adjuvant treatment. After completion of the adjuvant therapy, the patient was followed up for 7 year without recurrence. In 2012, anorectal pain was initiated and mass in the anal canal was detected at physical examination. Magnetic resonance imaging (MRI) revealed 7 cm diameter mass in anorectal region and colonoscopic biopsy was performed. Pathology examination showed good differentiated papillary lesion suggested that transitional cell carcinoma. The patients consider as recurrence of the urinary transitional cell carcinoma and treated with gemcitabin and cisplatin. After 6 cycles treatment, there was minimal regression in anorectal mass. Because of continuation of the anal pain after chemotherapy, concomitant radiotherapy with gemcitabin was performed and symptoms were relieved. After 2 years without follow up, patient presented with painful defecation. Thorax-abdominal computer tomography (CT) revealed increased size of anorectal mass and new multiple solid mass in right lung. Biopsy from new lung lesion was performed and histopathologic and immunohistochemistic examinations showed malignant epithelial tumor with positive p63 and negative CK20 and TTF-1 staging, consistent with the diagnosis of urotelial carcinoma metastasis. Therefore, gemcitabin and cisplatin therapy were initiated again and after 6 cycles, there was no response in anorectal mass and lung metastasis. Biopsy was repeated in anorectal mass and lung lesion because of confusion to the diagnosis due to refraction of the primary treatment. Histopathologic examination revealed transitional epithelium like neoplastic cell with papiller differentiation

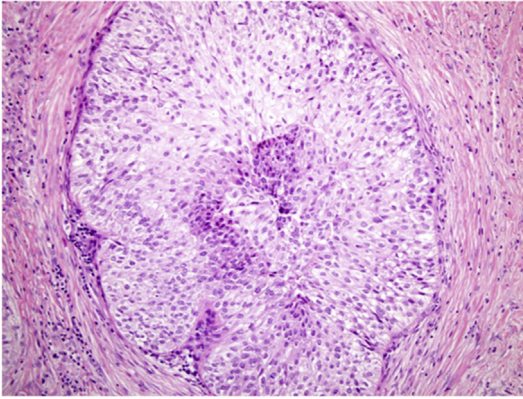
and negative staining with TTF-1, CK20, CDX2, CK 5/6 and positive staining with p63 were detected by immunohistochemistry (see Fig. 1). Results were consistent with diagnosis of anal cloacogenic carcinoma rather than uroepithelial transitional cell carcinoma. According to the last pathological examination, patient was consider as metastatic anal cloacogenic carcinoma and cisplatin – 5-Fluorouracil therapy were initiated. After 3 cycles of the treatment, there was partial response in anorectal and lung lesions. The symptoms of the patient were also relieved. Patient is still continue to therapy and there is no deterioration of his clinical situation.

Malign neoplasm originating in the anorectal area include mainly squamous-cell carcinoma, adenocarcinoma, melanoma, basal-cell carcinoma and neurogenic sarcoma. Anal is a very rare tumor of anorectal region. Firstly, Grinvasky et al. described anal canal cloacogenic cell carcinoma.<sup>2</sup> It accounts for approximately 2–3% of the all anal canal cancers.<sup>1</sup> Transitional or cloacogenic zone of anal canal located around of dentate line and anal cloacogenic tumor arise from cloacogenic remnant of the cloacal membrane of the embryo. The mucosa of the anal transitional zone occur several cell types including; basaloid, columnar, cuboidal, transitional (urothelium-like), and squamous cells. Thus, cloacogenic cancer occur many type of the histological pattern like as mucoepidermoid carcinoma-like, adenoid cystic carcinoma – like, transitional carcinoma like and basaloid with peripheral palisade. According to study that evaluated 27 patients with cloacogenic cancer, transitional carcinoma like variant and basaloid with peripheral palisade were found 10 of 27 patients and 13 of the 27 patients, respectively.<sup>3</sup> Because of, there is limited data about cloacogenic cancer in literature, these rare tumors can be misdiagnosed. Especially, as in or case, transitional variant of cloacogenic cancer can be generally misdiagnosed with anal canal metastasis of the urinary transitional carcinoma. The distinction between anal cloacogenic cancer and metastasis of the urinary transitional carcinoma can be made by histomorphologic examination and immunohistochemically staging. Anal cloacogenic cancer can be stained with cytokeratine 4, 13, 17, 18, 19 and this staining pattern distinct from anal squamous cell carcinoma. For distinction with urinary transitional carcinoma can be also made by uroplakin 2 and 3 that stained positive in urinary transitional carcinoma and no stained in anal cloacogenic cancer.<sup>4</sup> Surgery and radiotherapy are two treatment choice of local disease and most of the case who published in literature had local disease and treated by surgery and radiotherapy.

Peer review under responsibility of Turkish Society of Medical Oncology.

<http://dx.doi.org/10.1016/j.jons.2017.05.004>

2452-3364/© 2017 Production and hosting by Elsevier B.V. on behalf of Turkish Society of Medical Oncology. This is an open access article under the CC BY-NC-ND license (<http://creativecommons.org/licenses/by-nc-nd/4.0/>).



**Fig. 1.** Tumoral infiltration with transitional cell characterization (H&E; x200).

Bertani et al. published long term follow up results of the 7 cloacogenic carcinoma patients treated with concurrent chemoradiotherapy and 3 of the 7 patients were metastatic at the time of the diagnosis.<sup>5</sup> 5 years overall survival was found as 48% with concurrent chemoradiotherapy.

However, in our knowledge, there is limited data about treatment of the metastatic cloacogenic cancer of the anal canal. In our case, we administered cisplatin and 5-Fluorouracil and after 3 cycles, partial regression was occurred. This is the case who shown efficacy of the cisplatin and 5-Fluorouracil treatment without concomitant radiotherapy in metastatic stage. In the case who diagnosed with metastatic urinary transitional carcinoma arise from anal canal and refractor to standard treatment can be reevaluated for anal cloacogenic cancer.

## References

1. Klotz RG, Pamukcuoglu T, Souillard DH. Transitional cloacogenic carcinoma of the anal canal "Clinicopathologic Study of Three Hundred Seventy-three Cases". *Cancer*. 1967;20:1727–1745.
2. Grinvalsky HT, HE. Carcinoma of the anorectal junction, I. Histological consideration. *Cancer*. 1954;9.
3. Graham RP, et al. Basaloid squamous cell carcinoma of the anus revisited. *Am J Surg Pathol*. 2016;40:354–360.
4. WHO classification of tumours of the lung Travis WD, BE, Burke AP, Marx A, Nicholson AG, eds. *Pleural, Typhus Heart*. 2015. <http://dx.doi.org/10.1097/JTO.0000000000000630>.
5. Bertani E, et al. Aggressive treatment approach for cloacogenic carcinoma of the anorectum: report from a single cancer center. *Dig Surg*. 2010;27:297–301.

Burak Bilgin\*, Mehmet A.N. Sendur  
Yıldırım Beyazıt University, Faculty of Medicine, Department of  
Medical Oncology, Ankara, Turkey

Yetkin Ağaçkiran  
Ankara Atatürk Training and Research Hospital, Department of  
Pathology, Ankara, Turkey

Bülent Yalçın  
Yıldırım Beyazıt University, Faculty of Medicine, Department of  
Medical Oncology, Ankara, Turkey

\* Corresponding author. Yıldırım Beyazıt University, Faculty of  
Medicine, Department of Medical Oncology, 06100, Sıhhiye,  
Ankara, Turkey.  
E-mail address: [dr\\_bbilgin@yahoo.com](mailto:dr_bbilgin@yahoo.com) (B. Bilgin).

5 March 2017  
Available online 16 June 2017