



## A lung adenocarcinoma patient with EGFR mutation in exon 18 and ALK-rearrangement who treated with erlotinib and crizotinib

Mehmet Artaç<sup>a,\*</sup>, Levent Korkmaz<sup>a</sup>, Mustafa Karaağaç<sup>a</sup>, Buğra Kaya<sup>b</sup>, Necdet Poyraz<sup>c</sup>, Hakan Özön<sup>d</sup>, Zehra Er<sup>a</sup>, Lema Tavlı<sup>e</sup>

<sup>a</sup> Necmettin Erbakan University, Meram Faculty of Medicine, Department of Medical Oncology, Konya, Turkey

<sup>b</sup> Necmettin Erbakan University, Meram Faculty of Medicine, Department of Nuclear Medicine, Konya, Turkey

<sup>c</sup> Necmettin Erbakan University, Meram Faculty of Medicine, Department of Radiology, Konya, Turkey

<sup>d</sup> Istanbul Genetics Laboratory, Istanbul, Turkey

<sup>e</sup> Necmettin Erbakan University, Meram Faculty of Medicine, Department of Pathology, Konya, Turkey

### ARTICLE INFO

#### Article history:

Received 20 October 2017

Received in revised form

9 April 2018

Accepted 24 April 2018

Available online 3 May 2018

#### Keywords:

Non-small cell lung cancer

Erlotinib

Epidermal growth factor receptor

Anaplastic lymphoma kinase

Crizotinib

### ABSTRACT

Concomitant mutations of echinoderm microtubule-associated protein-like 4 (EML4) anaplastic lymphoma kinase (ALK) translocation and epidermal growth factor receptor (EGFR) can be found rarely in lung adenocarcinoma. We present a case of harboring EML4/ALK rearrangement lung adenocarcinoma who previously received erlotinib. A 42-year-old male who was diagnosed as lung adenocarcinoma and received many series of cytotoxic regimens. A partial tumor response was achieved with crizotinib after failure with erlotinib therapy. After progressive disease, biopsy of new liver lesion showed EML4/ALK rearrangement. Thus crizotinib was administrated. A partial tumor response was achieved with crizotinib after failure with erlotinib therapy and chemotherapy. We conclude that it is important to evaluate for EML4/ALK rearrangement even the patient has EGFR mutation. Concomitant EGFR exon 18 and EML4-ALK mutations can occur in lung adenocarcinoma. EML4/ALK related TKIs may be more effective in these patients.

© 2018 Turkish Society of Medical Oncology. Production and hosting by Elsevier B.V. This is an open access article under the CC BY-NC-ND license (<http://creativecommons.org/licenses/by-nc-nd/4.0/>).

### 1. Introduction

Sensitizing EGFR mutations were seen in near 10% of Caucasian patients with non-small lung cancer (NSCLC) and up to 50% of Asian patients. The echinoderm microtubule-associated protein-like 4 (EML4) and anaplastic lymphoma kinase (ALK) gene rearrangements occur up to 7% of patients with NSCLC.<sup>1</sup> In a study, 1.6% of 380 patients showed both EGFR and EML4-ALK mutations.<sup>2</sup> These mutations showed predictivity for response to specific tyrosine kinase inhibitors (TKIs) (gefitinib, erlotinib, or afatinib) for the cases with EGFR mutations<sup>3–5</sup> and crizotinib, alectinib, and ceritinib for the patients who have EML4/ALK translocation.<sup>6</sup>

Both EGFR and EML4/ALK mutations were reported in only four cases of 1458 lung cancer patients.<sup>7</sup> In that report, ALK inhibitors appeared to be more effective for cases with co-mutations. The

exon 18-EGFR mutations were demonstrated in 2.8% of lung adenocarcinomas. Single exon 18-EGFR mutation caused a worse survival than multiple EGFR exon of 18 mutations.<sup>8</sup>

In this case presentation, a case of harboring EML4/ALK rearranged lung adenocarcinoma who previously had an EGFR mutation in exon 18 and received erlotinib. A partial tumor response was achieved with crizotinib after failure with erlotinib therapy and chemotherapy.

### 2. Case report

A 42-year-old male, who smoked for 10 years but he had not been smoking since 5 years when he admitted our clinic, presented to our hospital with dyspnea in November 2010. Computed tomography (CT) scan revealed multiple nodules at left lung and multiple lymph nodes in mediastinum. Needle core biopsy was performed from the lung nodule. Adenocarcinoma histopathology was reported. The patient received 6 cycles of cisplatin plus docetaxel combination. Progressive disease was observed in CT. Exon 18 mutation P694S; nucleotide change (2080 C > T) in EGFR gene was

\* Corresponding author. Necmettin Erbakan University, Meram Medical Faculty, Department of Medical Oncology, 42080, Konya, Turkey.

E-mail address: [mehmetartac@yahoo.com](mailto:mehmetartac@yahoo.com) (M. Artaç).

Peer review under responsibility of Turkish Society of Medical Oncology.

detected in the tumor tissue (Fig. 1C). Due to detection of EGFR mutation ALK gene rearrangement was not studied at that time. Then erlotinib was started. After four months of erlotinib, brain metastasis occurred. Thus, the patient underwent 8 cycles of pemetrexed. Due to the development of atelectasis in left lung, palliative radiotherapy was performed. And then the patient was administered nine cycles of gemcitabine. Progression was seen in lung and abdominal CT with a new lesion in the liver (Fig. 1B). Biopsy was performed from the new liver lesion for assessing EML4/ALK rearrangement in May 2013 (Fig. 1A). Fluorescence in situ hybridization technique showed ALK gene rearrangement. Thus crizotinib was administered. PET CT scan showed regression in bone and liver lesions (Fig. 1D). In January 2015, progression of the brain lesion was seen in brain magnetic resonance imaging. Radiotherapy was performed to brain lesion. Then paclitaxel plus carboplatin combination was administered concurrent with crizotinib. After receiving three cycles of chemotherapy, treatment was discontinued due to worsening in performance status. After 6 months of drug-free follow up, increase in tumor size was demonstrated with chest CT scan. Then nivolumab was started. After one cycles of nivolumab the patient died.

### 3. Discussion

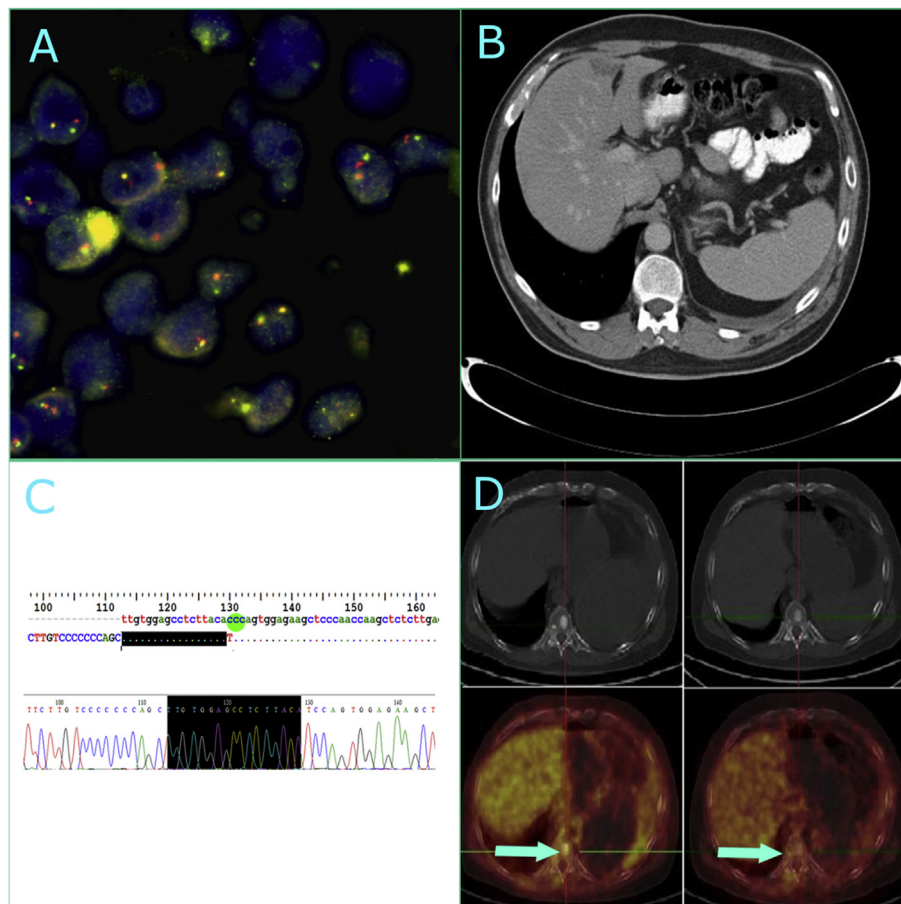
Concomitant EGFR and EML4/ALK alterations are seen rarely in lung adenocarcinoma. This phenomenon can, in fact, be explained by the concept of tumor heterogeneity according to which different mutations of tyrosine kinase receptors might coexist. In our case

biopsy from liver metastasis demonstrated the EML4/ALK rearrangement. We detected EGFR mutation in the primary tumor and ALK rearrangement in the liver metastases. This can show the importance of biopsies from the new metastatic sites, when it is possible. The probability of coexistence of ALK fusions and EGFR mutations should be kept in mind to treat these patients with each way.

Today, TKIs are effective therapies for lung cancer patients. Thus, detection of specific mutations in tumor is very important. Albeit rare, in present case we detected concomitant EGFR exon 18 mutation and EML4/ALK rearrangement. Although the patient had received erlotinib, brain metastases occurred after four months. This EGFR exon 18 mutation is a rare mutation and this patient did not benefit from EGFR TKI. The recent literature revealed that EGFR exon 18 mutations had a worse survival outcome than the other EGFR mutations.<sup>8</sup> However, the efficacy of crizotinib was remarkable with 19 months of progression-free. EML4/ALK rearrangement detection is clinically important and associated with marked crizotinib sensitivity. In early trials of crizotinib, the rate of objective response was 60% and median progression free survival was found up to 10 months in NSCLC patients.<sup>9,10</sup>

### 4. Conclusion

Detection of mutations in new metastatic sites could be very important. Concomitant EGFR exon 18 and EML4-ALK mutations can occur in lung adenocarcinoma. EML4/ALK related TKIs may be more effective in these patients.



**Fig. 1.** A) EML4/ALK rearrangement in 90% of cells. B) Liver lesion in computed tomography. C) Homozygous c.2080c > T (p.P694s) mutation in exon 18 of EGFR gene was detected from the tumor tissue D) PET CT scan showed regression in bone and liver lesions.

## References

1. Ettinger DS, Wood DE, Akerley W, et al. Non-small cell lung cancer, version 6.2015 [cited 2016 Jan 30] *J Natl Compr Canc Netw*. 2015;13:515–524. Available from: <http://www.ncbi.nlm.nih.gov/pubmed/25964637>.
2. Ulivi P, Chiadini E, Dazzi C, et al. Nonsquamous, non-small-cell lung cancer patients who carry a double mutation of EGFR, EML4-ALK or KRAS: frequency, clinical-pathological characteristics, and response to therapy. *Clin Lung Canc*; 2015 Dec 1 [cited 2016 Jan 30]; Available from: <http://www.ncbi.nlm.nih.gov/pubmed/26712101>.
3. Mok TS, Wu Y-L, Thongprasert S, et al. Gefitinib or carboplatin–paclitaxel in pulmonary adenocarcinoma. *N Engl J Med*. 2009;361:947–957. Available from: <https://doi.org/10.1056/NEJMoa0810699>.
4. Rosell R, Carcereny E, Gervais R, et al. Erlotinib versus standard chemotherapy as first-line treatment for European patients with advanced EGFR mutation-positive non-small-cell lung cancer (EURTAC): a multicentre, open-label, randomised phase 3 trial [cited 2015 Dec 15] *Lancet Oncol*. 2012;13:239–246. Available from: <http://www.ncbi.nlm.nih.gov/pubmed/22285168>.
5. Yang JC-H, Wu Y-L, Schuler M, et al. Afatinib versus cisplatin-based chemotherapy for EGFR mutation-positive lung adenocarcinoma (LUX-Lung 3 and LUX-Lung 6): analysis of overall survival data from two randomised, phase 3 trials [cited 2016 Jan 27] *Lancet Oncol*. 2015;16:141–151. Available from: <http://www.ncbi.nlm.nih.gov/pubmed/25589191>.
6. Gainor JF, Sherman CA, Willoughby K, et al. Alectinib salvages CNS relapses in ALK-positive lung cancer patients previously treated with crizotinib and ceritinib [cited 2016 Apr 5] *J Thorac Oncol*. 2015;10:232–236. Available from: <http://www.pubmedcentral.nih.gov/articlerender.fcgi?artid=4304931&tool=pmcentrez&rendertype=abstract>.
7. Won JK, Keam B, Koh J, et al. Concomitant ALK translocation and EGFR mutation in lung cancer: a comparison of direct sequencing and sensitive assays and the impact on responsiveness to tyrosine kinase inhibitor [cited 2016 Jan 30] *Ann Oncol*. 2015;26:348–354. Available from: <http://www.ncbi.nlm.nih.gov/pubmed/25403583>.
8. Cheng C, Wang R, Li Y, et al. EGFR exon 18 mutations in East Asian patients with lung adenocarcinomas: a comprehensive investigation of prevalence, clinicopathologic characteristics and prognosis [cited 2016 Feb 5] *Sci Rep*. 2015;5:13959. Available from: <http://www.pubmedcentral.nih.gov/articlerender.fcgi?artid=4564802&tool=pmcentrez&rendertype=abstract>.
9. Camidge DR, Bang Y-J, Kwak EL, et al. Activity and safety of crizotinib in patients with ALK-positive non-small-cell lung cancer: updated results from a phase 1 study [cited 2016 Jan 6] *Lancet Oncol*. 2012;13:1011–1019. Available from: <http://www.pubmedcentral.nih.gov/articlerender.fcgi?artid=3936578&tool=pmcentrez&rendertype=abstract>.
10. Kwak EL, Bang Y-J, Camidge DR, et al. Anaplastic lymphoma kinase inhibition in non-small-cell lung cancer [cited 2014 Dec 3] *N Engl J Med*. 2010;363:1693–1703. Available from: <http://www.pubmedcentral.nih.gov/articlerender.fcgi?artid=3014291&tool=pmcentrez&rendertype=abstract>.